

The structure and function of the Bony pelvis

December 2018
MD6 program

Vasilios Tanos MD, PhD
Professor in Obstetrics and Gynaecology



Aretaeio Hospital

Disclosure



G E S E A

Development
Education
Surgical
Education and
Assessment

Chairman



Womana Medical Services

Director

www.womana.com.cy

European
+theAcademy of
Gynaecological
Surgery

**European Academy
of Gynaecological Endoscopic Surgery**

Scientific Director

www.europeanacademy.org



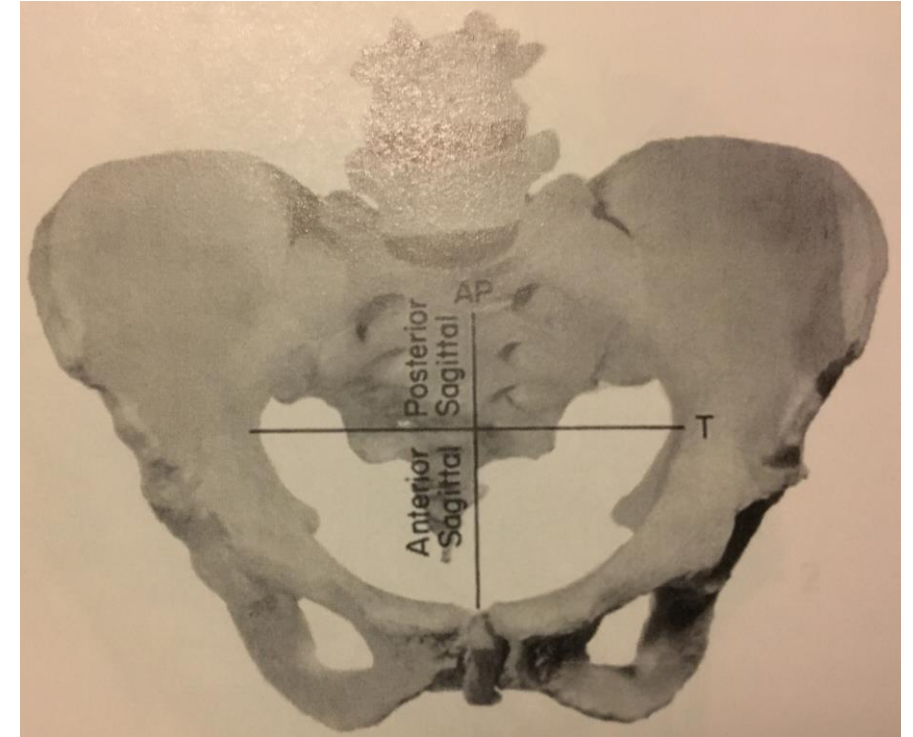
**ESHRE Certification of Reproductive
Endoscopic Surgery (ECRES) committee**

Coordinator

www.eshre.eu

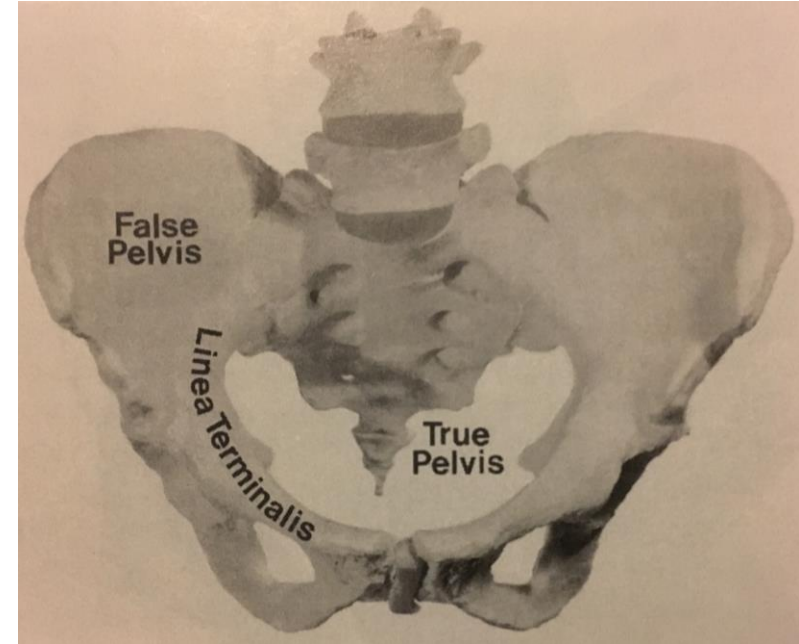
The bony pelvis

- Body weight is transmitted to lower extremities
- In women pelvis adapts to pregnancy and delivery
- Composed of 4 bones sacrum, coccyx and 2 innominate bones
- Innominate bone is formed by:
 - the fusion of the ilium, ischium and pubis
 - Sacroiliac synchondroses
 - Symphysis pubis



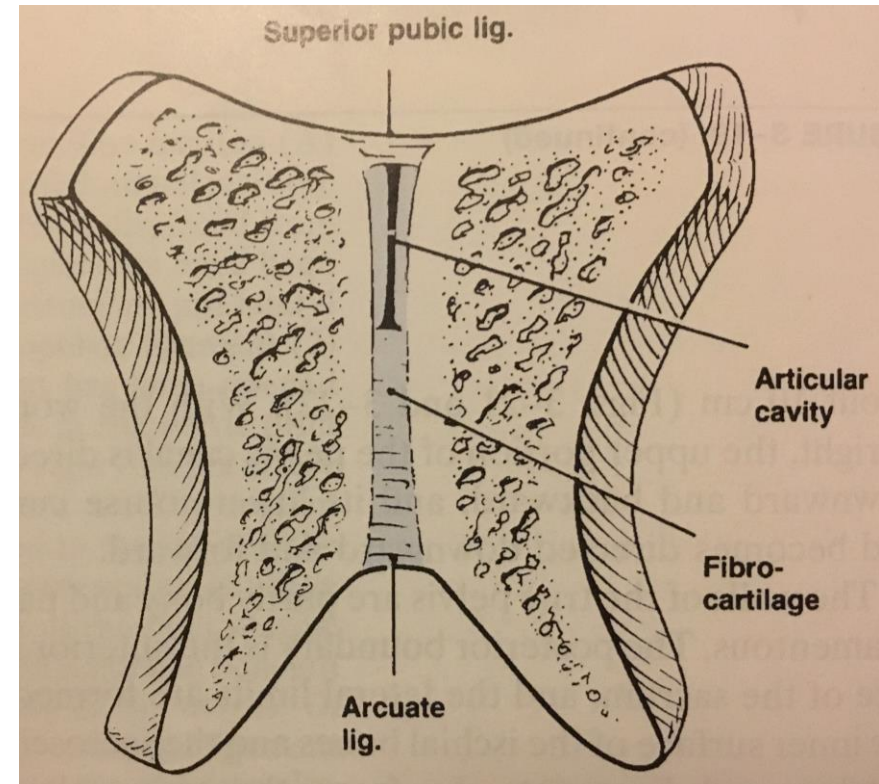
Pelvic anatomy

- False pelvis lies above the linea terminalis
 - Bounded posteriorly by the lumbar vertebrae
 - Laterally by the iliac fossae
 - Front by the lower portion of the anterior abdominal wall
- True pelvis - important for pregnancy and delivery (Directed downwards and backwards)
 - Above by promontory, sacrum alae, linea terminalis, upper margins of pubic bones
 - Below by the pelvic outlet
 - Posterior wall is the sacrum (*straight line from promontory to the tip of the sacrum is 10cm and distance along the concavity is about 12cm*)



Pelvic joints

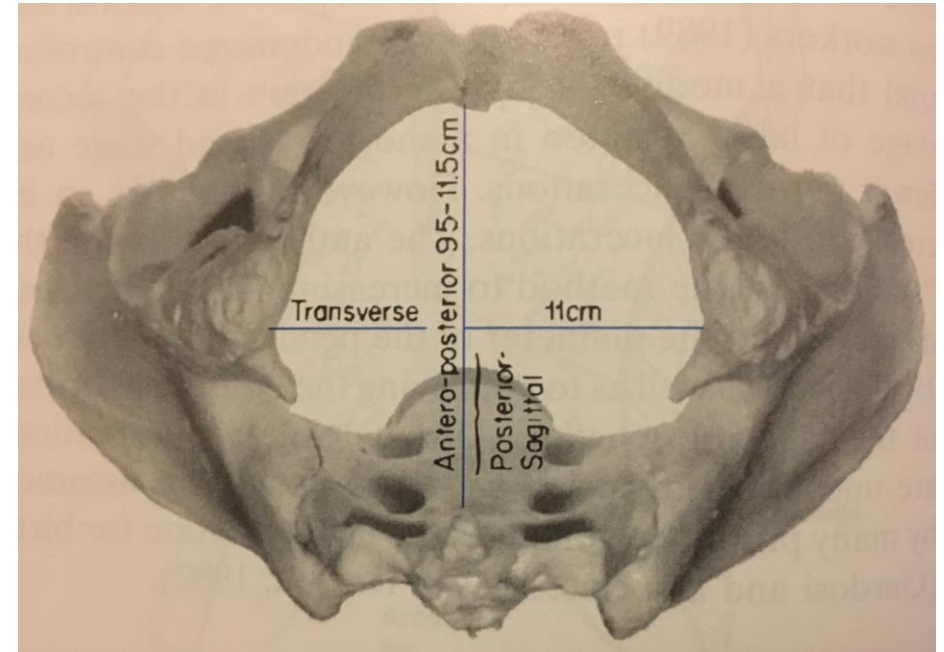
- Symphysis pubis (superior and inferior ligaments)
- Arcuate ligament of the pubis
- Sacroiliac joints - posteriorly between the sacrum and the iliac portion



Pelvis with 4 imaginary planes

Human female pelvis is typically more nearly round -50% in white women

- Pelvic inlet (superior straight)
 - Posteriorly by the promontory sacrum alae
 - Laterally by the linea terminalis
 - Anteriorly by the horizontal rami of the pubic bones and Symphysis pubis
- Pelvic outlet (inferior straight)
- Midpelvis (least pelvis dimensions)
- Greatest pelvic dimensions

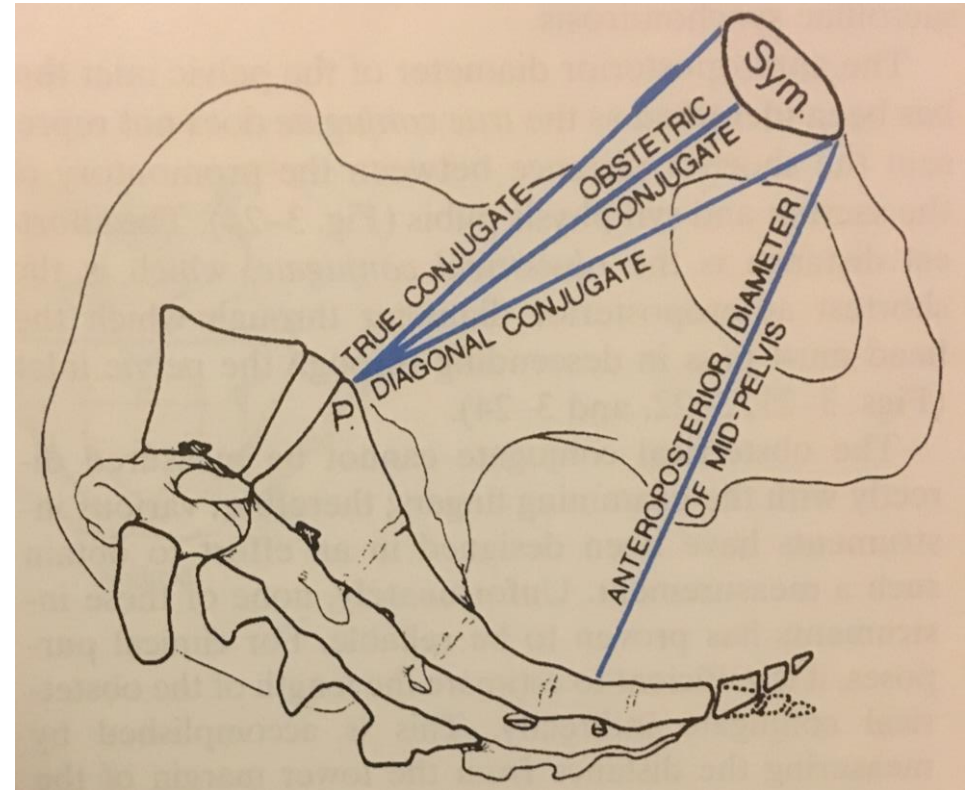
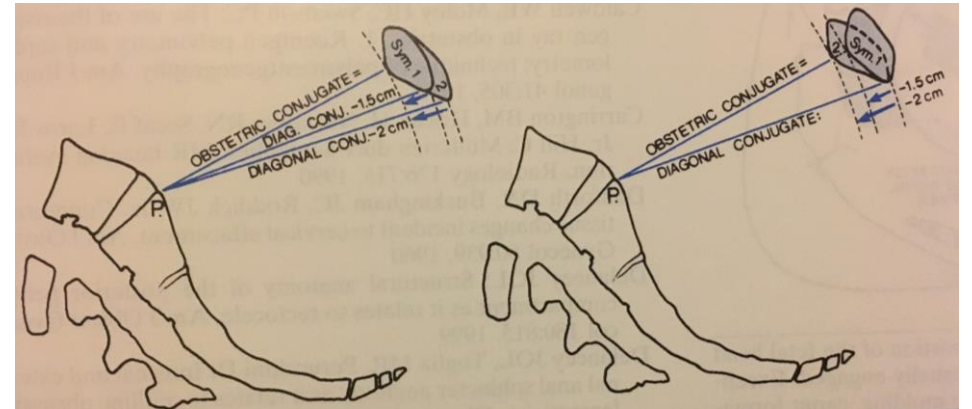


Pelvic outlet

Anteroposterior diameter can be divided into anterior and posterior sagittal diameters

Pelvic Inlet

- Anteroposterior
 - **Obstetrical conjugate** = shortest distance between the promontory and SP ~ 10cm
 - **True conjugate** = shortest anteroposterior diameter
 - **Diagonal conjugate** = distance from lower margin of the SP to promontory
- Transverse = greatest distance between the linea terminalis on either side
 - The segment of the obstetrical conjugate from the intersection of these 2 lines to the promontory is the posterior sagittal diameter of the inlet
- 2 obliques
 - From sacroiliac synchodroses to iliopectineal eminence on the opposite side of the pelvis ~13cm



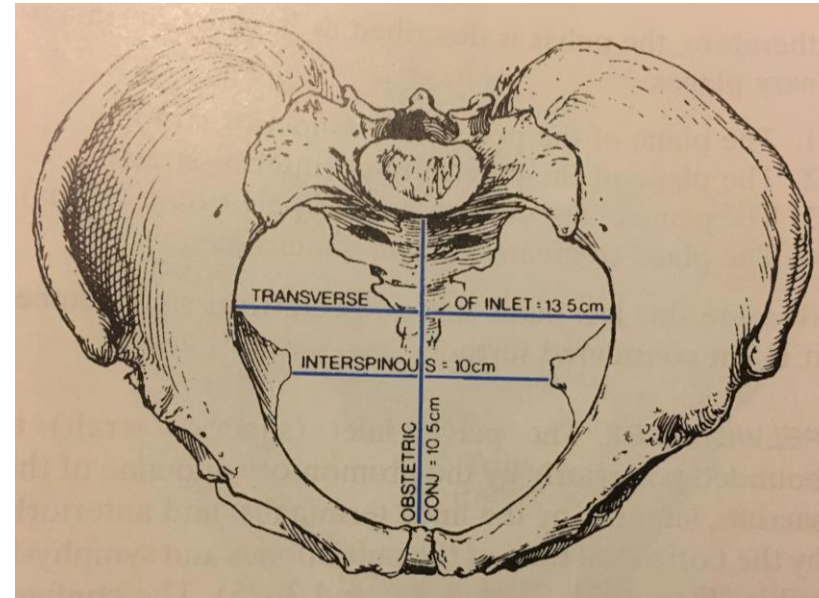
3 anteroposterior diameter of the pelvic inlet

Mid-pelvis

- Level of the ischial spines
plane of the least pelvic dimensions
- Interspinous diameter 10cm,
smallest diameter of the pelvis

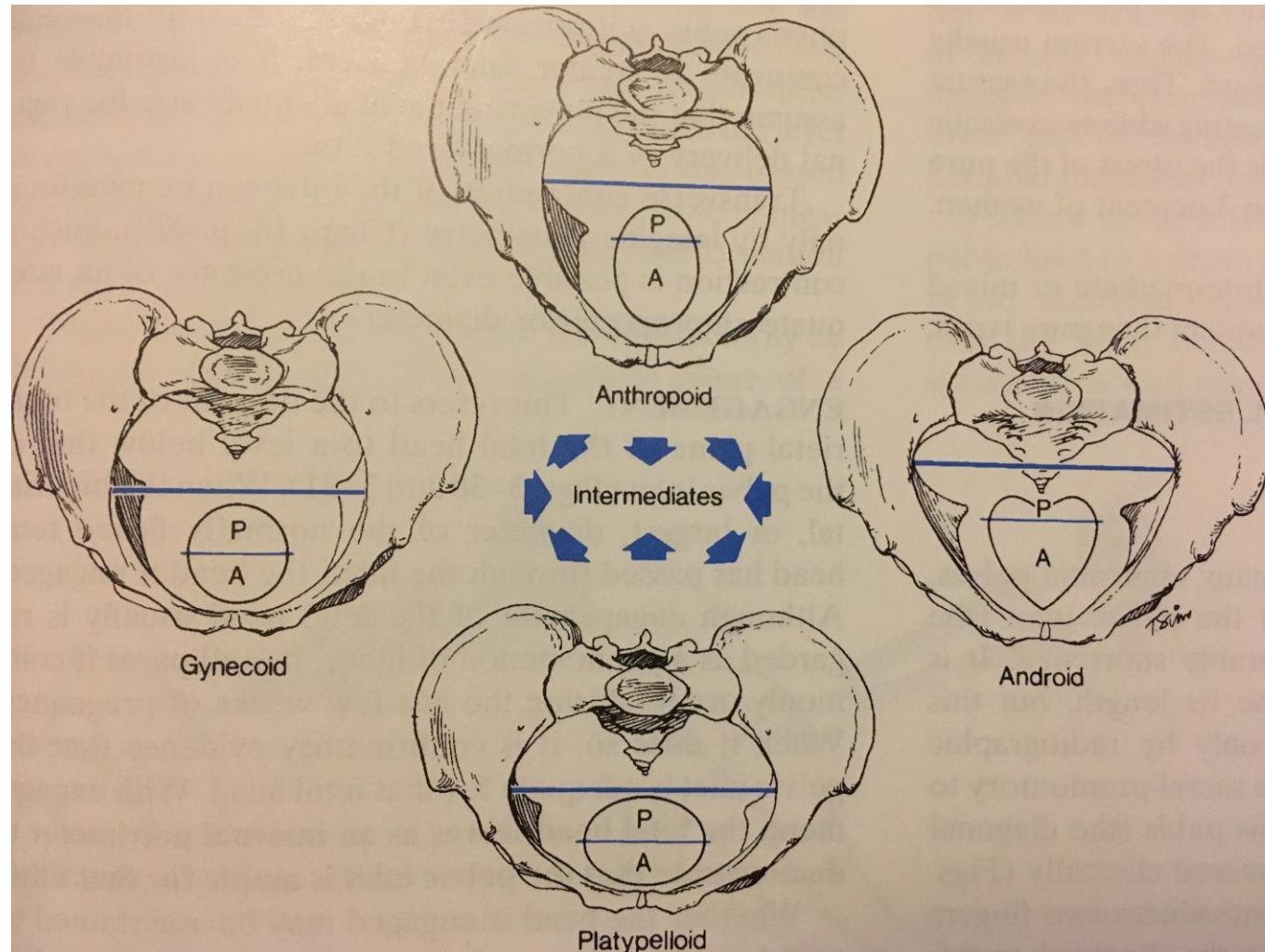
Pelvic outlet

- Anterior triangle – under the pubic arch
- Anteroposterior 9.5 – 11.5 cm
- Transverse 11cm
- Posterior sagittal > 7.5cm

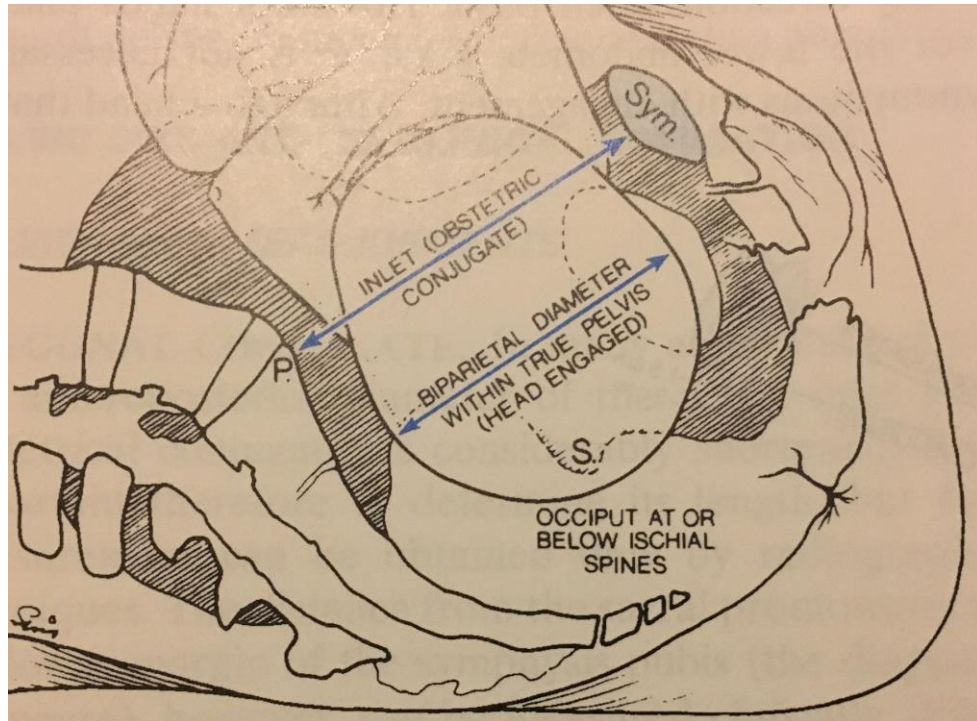


- Anteroposterior and transverse diameters of the pelvic inlet
- Transverse (interspinous) diameter of the midpelvis
- Obstetrical conjugate is normally > 10cm

Pelvic shapes

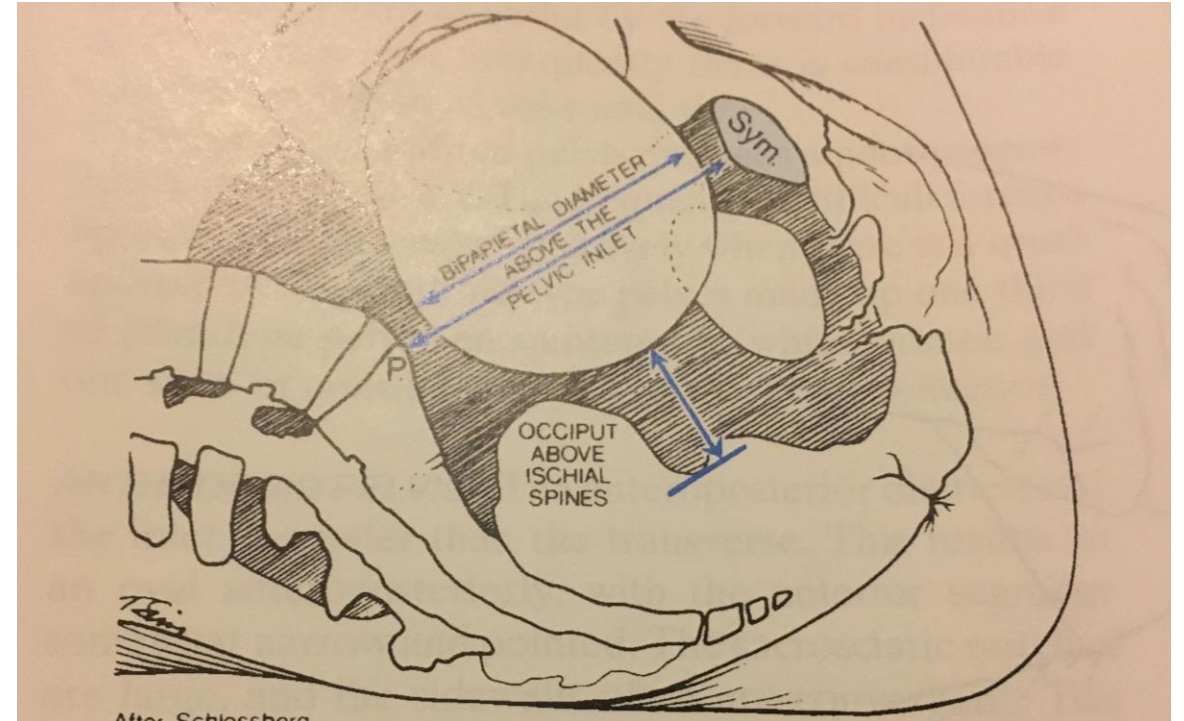


Engagement – descent of the biparietal plane of the fetal head to the level below that of the pelvic inlet

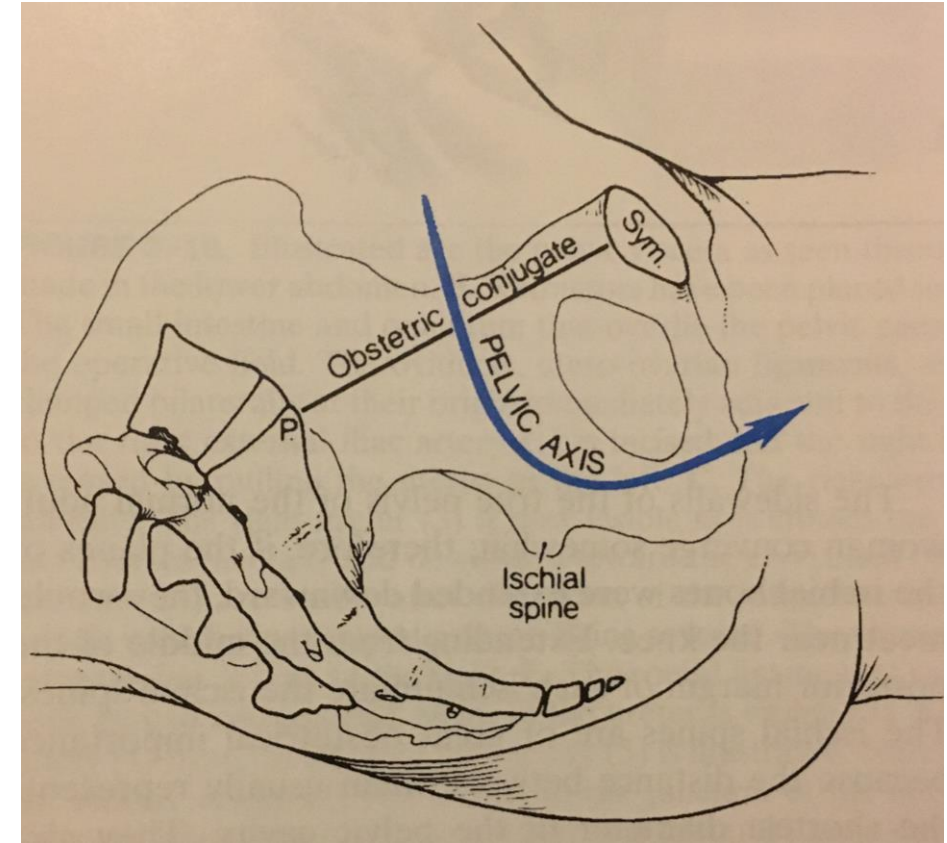
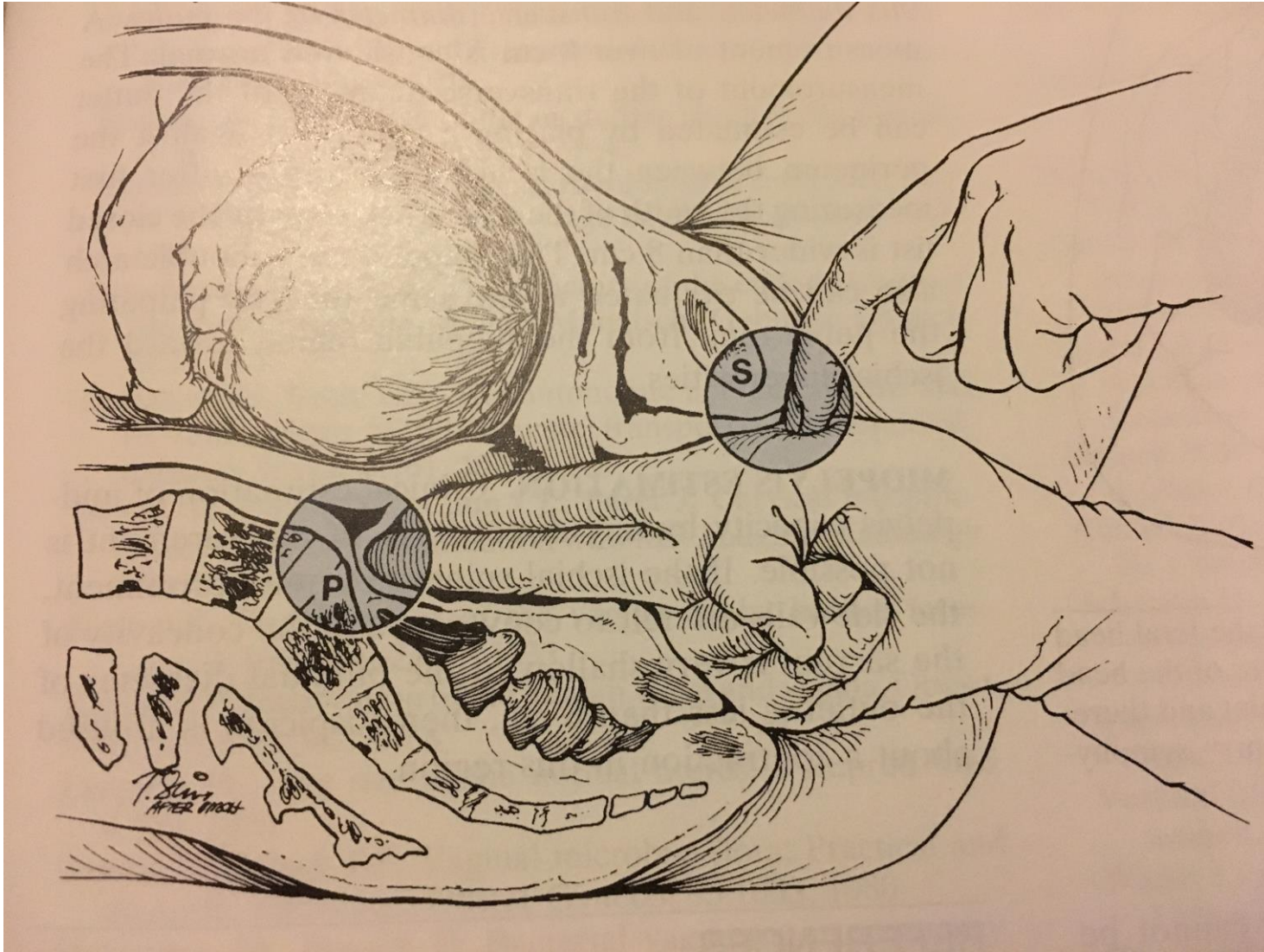


Engaged Fetal head is at or below the ischial spines

S = ischial spines



When the lowermost portion of the fetal head is above the ischial spines, the BPD of the head is not likely to have passed through the pelvic inlet and therefore is not engaged



The cavity of the true pelvis is comparable to an obliquely truncated, bent cylinder with its greatest height posteriorly. Note the curvature of the pelvic axis.